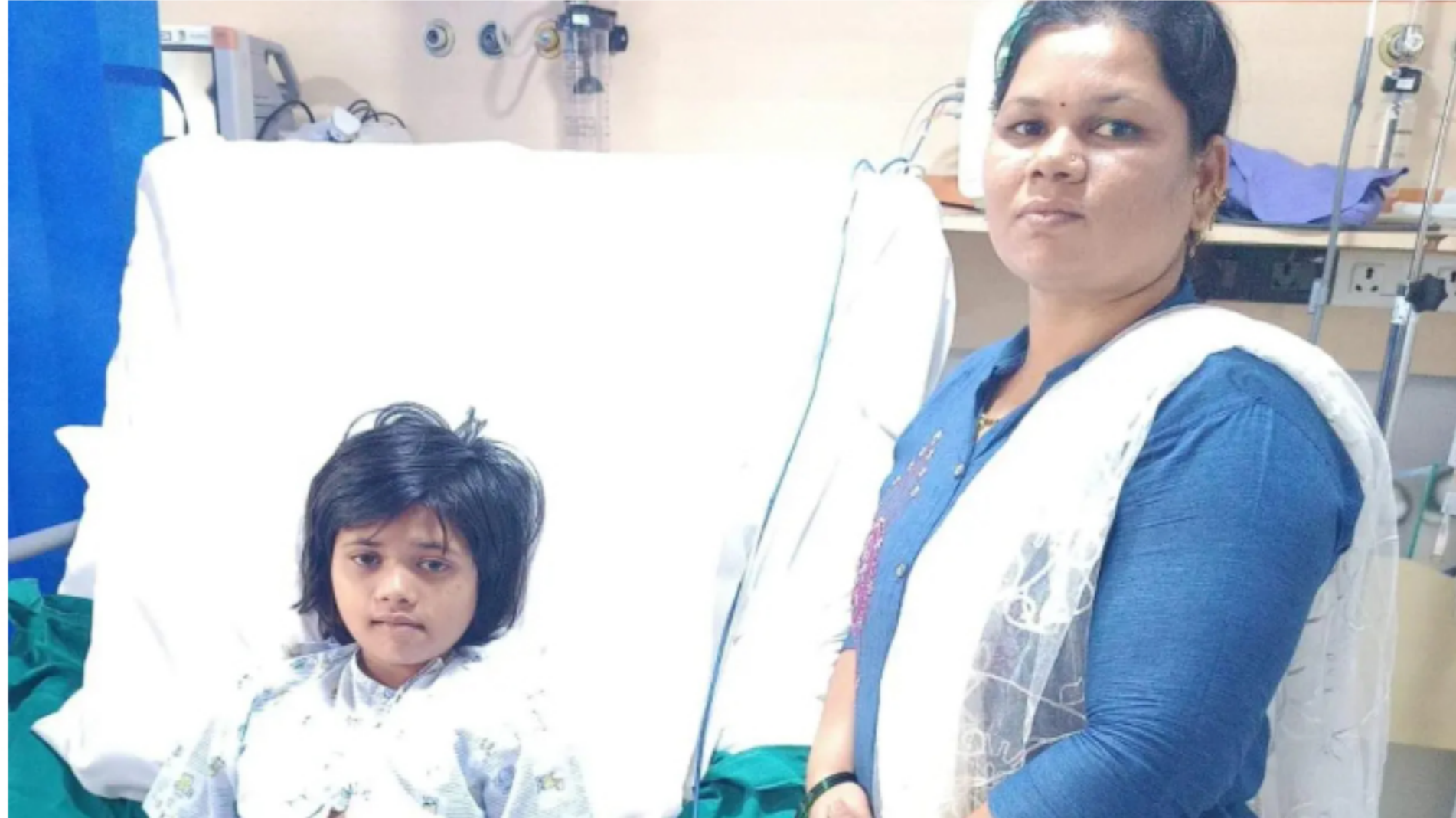


Mumbai doctors help Sangli girl survive life-threatening rare paediatric pancreatic complication

Updated on: 06 January, 2025 02:34 PM IST | Mumbai
mid-day online correspondent |

The girl was found to have pancreatitis due to her genetic disposition. Consequently, she developed a pancreatic pseudocyst which led to an aneurysm in the gastroduodenal artery (GDA), that ultimately ruptured, and resulted in acute pain.



The patient, Aditi Kamble, experienced symptoms such as acute abdominal pain one week ago. Photo Courtesy: Lilavati Hospital



Mumbai doctors have successfully treated a rare and life-threatening pancreatic condition in a 13-year-old girl from Sangli in Maharashtra. The patient was detected with pseudoaneurysm in the gastroduodenal artery in the pseudocyst of the pancreas along with pancreatitis which was successfully managed by a minimally invasive procedure guided by angiography, performed by Dr Rahul Sheth, an interventional radiologist. This procedure not only alleviated her pain but also offered a lasting solution to her complex condition. The team of experts at Lilavati Hospital and Research Centre was led by Dr Rajeev Redkar, paediatric surgeon along with Dr Aniruddha Phadke, gastroenterologist with paediatricians Dr Deepak Ugra and Dr Minhaj Sheikh, and Dr Sheth.

The patient, Aditi Kamble, experienced symptoms such as acute abdominal pain one week ago. The young girl, who has a family history of pancreatic disease, was diagnosed with acute pancreatitis two years ago. Her family sought the advice of a gastroenterologist but her condition didn't improve. She continued to have intermittent pain in her abdomen. Last week, she experienced severe abdominal pain accompanied by vomiting which interfered with her daily routine. She visited another hospital in Mumbai where her condition could not be managed. After that, the patient was admitted to Lilavati Hospital for this life-saving intervention.

Dr Redkar said, "The patient was in distress due to unbearable abdominal pain on arrival in the hospital. Her abdomen CT scan revealed a pseudocyst (a fluid-filled mass in the pancreas) and a leaking pseudo-aneurysm of the gastro-duodenal artery within the pseudocyst, a rare and critical condition, especially in children. The patient suffered from this condition due to genetic factors as her father also struggled with pancreatic disease. After the pancreatitis resolved, she was detected with pseudocyst of the pancreas and pancreatitis (swelling and inflammation of the pancreas). The incidence of the leaking pseudoaneurysm in a pseudocyst of the pancreas is a very rare problem probably found in 1 in 10, 00,000 children with pancreatitis. The girl also had a dilated pancreatic duct and stones within her pancreas which further compromised the functioning of the pancreatic gland. The compromised pancreatic function caused stunted growth and acute on chronic abdominal pain."

He added, "In collaboration with interventional radiologists, advanced angiographic techniques were utilised to approach and coil the aneurysm, successfully stopping the active bleeding and obliterating the aneurysm. This uneventful procedure called angiographic embolisation of the gastroduodenal artery (GDA) aneurysm lasted for one hour. The patient was discharged after one week in a stable condition. Her pain is resolved and follow-up sonography has shown no recurrence. Not treating her at the right time could have raised the risk of complications like bleeding inside the pseudo pancreatic cyst. This case highlights Lilavati Hospital's commitment to delivering life-saving care for the patients."

"We are deeply thankful to Dr Rajeev Redkar and his team for their exceptional care and expertise. They not only saved my daughter's life but also gave us hope by managing her condition. She is excited to return to school and spend time with her friends," said the patient's mother expressing his gratitude for the timely intervention.

"Our team at Lilavati Hospital is committed to providing the highest level of care, and the successful treatment of this young patient is a testimony to unmatched care and dedication. With the help of the latest technology and expertise, together we tackle even the rarest and most complex conditions. This case highlights the power of teamwork, advanced medical care, and our relentless focus on improving patient outcomes. We're proud to have saved this child's life and offer a brighter future for her," concluded Dr Niraj Uttamani, chief operating officer at the Bandra hospital.